

# Invasive Lobular Carcinoma of the Breast with Extracellular Mucin- A New Rare Variant

VAIBHAV BHIKA BARI<sup>1</sup>, SANDHYA UNMESH BHOLAY<sup>2</sup>, KAVITA CHANDRAHAS SANE<sup>3</sup>

## ABSTRACT

Historically, extracellular mucin secretion is by default a feature of ductal carcinoma. Lobular carcinoma is known to be associated with only intracytoplasmic mucin production and signet ring cells. As ductal carcinoma and lobular carcinoma have different therapeutic and prognostic implications, it is important to classify them into respective groups. Here, we present a case of invasive lobular carcinoma with abundant extracellular and intracellular mucin in a 38-year-old female patient. Invasive lobular carcinoma with extracellular mucin is an extremely rare and new variant. Only 3 cases are reported in the literature so far.

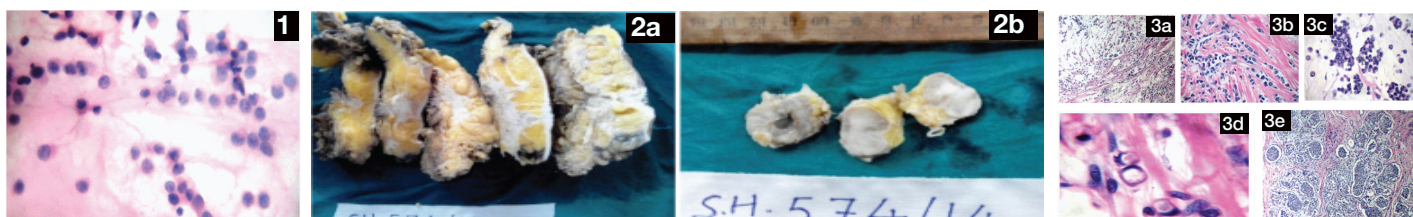
**Keywords:** E-cadherin, Mucicarmine, Signet ring

## CASE REPORT

A 38-year-old premenopausal woman presented with a mass in left breast since three years. A single palpable mass measuring 3.5 X 2.5 X 2 cm was present in upper outer quadrant of left breast. The nipple and areola were unremarkable. The FNAC of mass was performed which yielded small uniform cells with scanty cytoplasm arranged in linear dyscohesive pattern [Table/Fig-1]. The diagnosis of lobular carcinoma was rendered. Subsequently, patient underwent modified radical mastectomy with ipsilateral axillary dissection. The formalin fixed tissue sections were processed by routine histotechnical processes and stained by Hematoxylin & Eosin. Mucicarmine stain was performed to confirm the presence and location of mucin. Immunohistochemical stains were performed for Estrogen Receptor(ER), Progesterone Receptor (PR), HER 2 / neu, E- cadherin, Chromogranin A and Synaptophysin. On gross examination, a grey white tumour measuring 3.5 X 2.5 X 2 cm was seen in upper outer quadrant 0.7 cm away from the base and 0.5 cm away from the skin [Table/Fig-2a]. Ten axillary lymph nodes were

dissected, largest measuring 3X3X2.5 cm. The cut surfaces of the tumour and the larger lymph nodes were glistening [Table/Fig-2b].

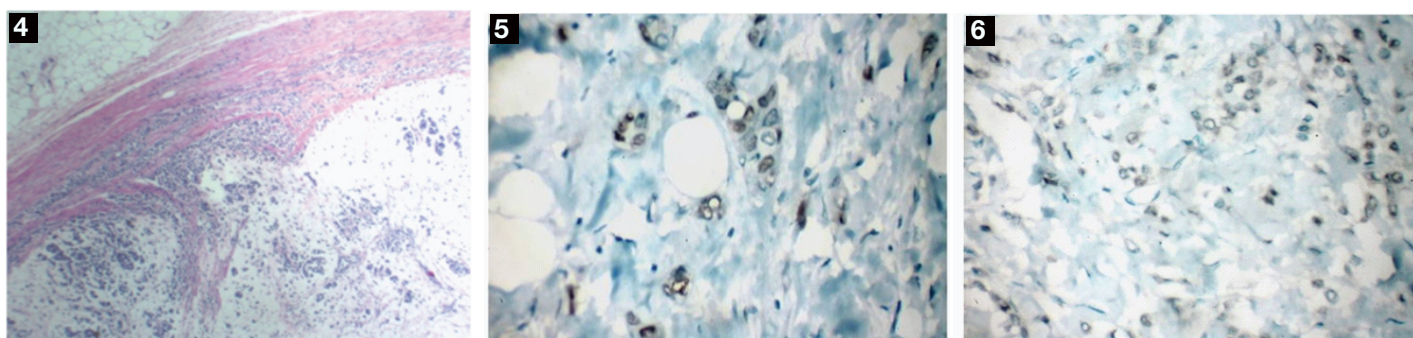
Microscopic examination revealed presence of abundant extracellular mucin [Table/Fig-3a-3e]. Nests of small to medium sized uniform tumour cells were floating in the mucin [Table/Fig-3a,3c]. At places, stromal infiltration by single cells was seen in Indian file pattern [Table/Fig-3b]. Some of the cells showed signet ring cell morphology and occasional cell showed intracytoplasmic mucin droplet [Table/Fig-3d]. Areas of lobular carcinoma in situ were noted [Table/Fig-3e]. The tumour was seen infiltrating underlying muscle and nerve bundles. Lymphovascular emboli were noted. Two lymph nodes showed replacement by tumour cells with similar features as in breast tumour [Table/Fig-4]. ER and PR were weakly positive [Table/Fig-5,6]. E-cadherin & Her 2 /neu were negative [Table/Fig-7,8]. Synaptophysin and Chromogranin A [Table/Fig-9,10] were negative. Mucicarmine stain confirmed abundant extracellular mucin production [Table/Fig-11].



[Table/Fig-1]: FNAC breast lump showing uniform cells in linear dyscohesive pattern

[Table/Fig-2a,b]: Gross photograph. 2a) The cut surface of the gross specimen showing grey white tumour. 2b) The cut surfaces of two larger lymph nodes showing replacement by tumour with glistening appearance

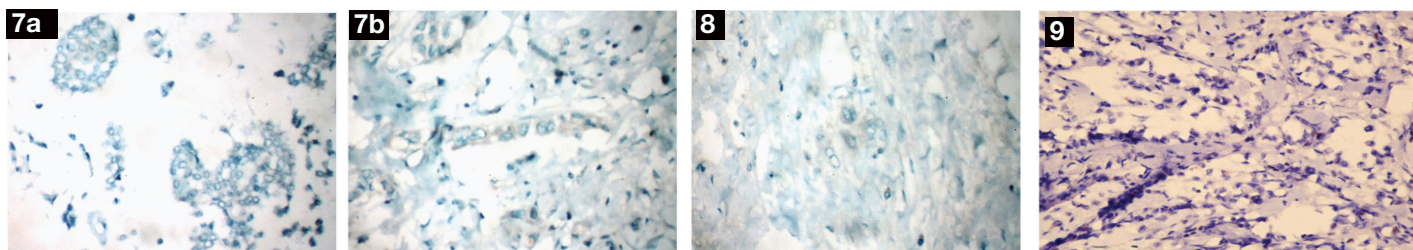
[Table/Fig-3a-e]: Histopathologic findings. 3a) Section showing nests of tumour cells in abundant extracellular mucin and areas with Indian file stromal infiltration (H&E stain, x 40). 3b) Section showing areas with Indian file stromal infiltration (H&E stain, x 100). 3c) Section showing nests of uniform tumour cells in abundant extracellular mucin (H&E stain, x 400). 3d) Section showing cells with signet ring morphology and intracytoplasmic mucin droplets (H&E stain, x 400). 3e) Section showing in situ lobular carcinoma (H&E stain, x 100)



[Table/Fig-4]: Microphotograph of lymph node with replacement by tumour cells with similar morphological features (H&E stain, x 40)

[Table/Fig-5]: Immunohistochemical stain for ER showing weak nuclear positivity in invasive tumour (ER,x100)

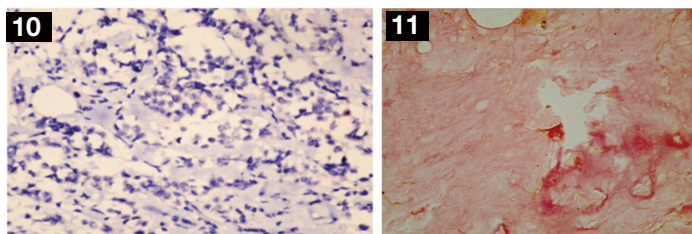
[Table/Fig-6]: Immunohistochemical stain for PR showing weak nuclear positivity in invasive tumour (PR, x100)



**[Table/Fig-7a,b]:** Immunohistochemical stain for E- cadherin 7A. Section showing E- cadherin negativity in tumour nests( E-cadherin,x100). 7B. Section showing E- cadherin negativity in tumour cells with Indian file pattern (E-cadherin,x100)

**[Table/Fig-8]:** Immunohistochemical stain for HER 2/neu. Section showing HER 2/ neu negativity in tumour cells (HER 2/neu,x100)

**[Table/Fig-9]:** Immunohistochemical stain for Synaptophysin. Section showing Synaptophysin negativity in tumour cells (Synaptophysin,x100)



**[Table/Fig-10]:** Immunohistochemical stain for Chromogranin A. Section showing Chromogranin A negativity in tumour cells (Chromogranin A, x100)

**[Table/Fig-11]:** Mucicarmine histochemical staining showing abundant extracellular mucin in tumour (Mucicarmine, x100)

expression was absent. HER- 2 / neu overexpression is a feature of invasive ductal carcinoma and not a feature of classical invasive lobular carcinoma. Rosa et al., [9] and Haltas et al., [6] observed that, their cases of lobular carcinoma with extracellular mucin did not overexpress HER-2 / neu, as in our case. On the other hand, Yu et al., [10] found overexpression of HER 2 /neu in their case study. According to them, this tumour was between lobular and ductal carcinoma with overlapping morphology and molecular profile. Thus, extracellular mucin production is not an exclusive feature of ductal phenotype. In spite of presence of extracellular mucin, when characteristic histological features of ILC are present, it is prudent to perform E-cadherin immunostain for confirmation of diagnosis.

## DISCUSSION

Invasive lobular carcinoma (ILC) occurs in older women constituting 5-15% of the breast carcinomas with greater incidence of distant metastasis [1]. Histologically, ILC is characterized by presence of small, relatively uniform cells growing singly in an Indian file [2]. Commonly ILC cells show intracellular acidic mucosubstances, sometimes giving them signet ring morphology [3,4].The known variants of ILC are solid, alveolar, tubulolobular, pleomorphic, signet ring and mixed [1]. In breast tumours, the extracellular mucin production is a feature of ductal tumour [4,5]. In our case report, lobular carcinoma with pools of extracellular mucin was seen. It is important for a pathologist to recognize ILC with extracellular mucin, because of differential diagnosis. The differential diagnoses include pure mucinous carcinoma, mucinous carcinoma with neuroendocrine differentiation, mixed mucinous-ductal carcinoma, mixed lobular and ductal carcinoma [6].

In the breast tumours, E-cadherin is a marker of choice to differentiate between ductal and lobular phenotype [4,5]. The tumour cells of ductal carcinoma show typical membranous positivity for E-cadherin. The cells of lobular carcinoma show loss of E-cadherin expression. In our case, tumour was composed of clusters of neoplastic cells floating in large pools of mucin and classical lobular carcinoma areas. The complete loss of membranous E-cadherin staining in all areas of tumour in both invasive and in situ component was seen. We used Mucicarmine to see presence of extracellular mucin. Neuroendocrine carcinoma of the breast can be differential diagnosis of ILC as it shows small tumour cells and can be associated with mucin production [2]. In order to rule out neuroendocrine differentiation in our case, we have performed Chromogranin A and Synaptophysin staining, results of which were negative. About 70-95% of lobular carcinomas are ER positive and 60-70% PR positive [7,8]. In our case, ER and PR expression was low and HER 2 / neu

## CONCLUSION

We have reported a very rare case of lobular carcinoma with extracellular mucin production.

## ACKNOWLEDGEMENT

We acknowledge the Department of Histopathology of Tata Memorial Hospital, Mumbai, India and Metropolis Laboratories, Mumbai, India for performing immunohistochemical stains.

## REFERENCES

- [1] IO Ellis, et al. Invasive breast carcinoma. In: Tavassoli FA, Devilee P, editors. WHO classification of Tumours of the breast and Female genital organs. Lyon: IARC Press, 2003;23-26.
- [2] Rosai J Breast. In: Rosai J. eds, Rosai and Ackermans Surgical Pathology, 10<sup>th</sup> ed. Mosby, An Imprint of Elsevier, 2011; 1659-1770.
- [3] Martinez V, Azzopardi JG. Invasive lobular carcinoma of breast: incidence and variants. *Histopathology*. 1979;3:467-88.
- [4] Rosen PP. Invasive lobular carcinoma. In: Rosen PP, editor. Rosen's Breast pathology. 3<sup>rd</sup> ed . Philadelphia: Lippincott Williams and Wilkins, 2009;690-705.
- [5] Lal P, Tan LK, Chen B. Correlation of HER-2 status with estrogen and progesterone receptors and histologic features in 3655 invasive breast carcinomas. *Am J Clin Pathol*. 2005;123:541-46.
- [6] Haltas H, Bayrak R, Yenidunya S, Kosehan D, Sen M, Akin K. Invasive lobular carcinoma with extracellular mucin as a distinct variant of lobular carcinoma: a case repor. *Diagnostic Pathology*. 2012;7:91.
- [7] Sastre- Garau X, Jouve M, Asselain B, Vincent- Salomon A, Beuzeboc P, Dorval T, Durand JC, et al. Infiltrating lobular carcinoma of the breast . Clinicopathological analysis of 975 cases with reference to data on conservative therapy and metastatic pattern. *Cancer*. 1996;77:113-20.
- [8] Zafrani B, et al. High sensitivity and specificity of immunohistochemistry for detection of hormone receptors in breast carcinoma: comparison with biochemical determination in a prospective study of 793 cases. *Histopathology*. 2000;37:536-45.
- [9] Rosa M, Mohammadi A, Masood S. Lobular carcinoma of the breast with extracellular mucin: new variant of mucin producing carcinomas? *Pathology International*. 2009;59:405-09.
- [10] Yu J, Bhargava R, Dabbs DJ. Invasive lobular carcinoma of the breast with extracellular mucin production and HER-2 overexpression: a case report and further case studies. *Diagn Pathol*. 2010;15:5-36.

### PARTICULARS OF CONTRIBUTORS:

1. Assistant Professor, Department of Pathology, Rajiv Gandhi Medical College, Kalwa, Maharashtra, India.
2. Associate Professor, Department of Pathology, Rajiv Gandhi Medical College, Kalwa, Maharashtra, India.
3. Associate Professor, Department of Pathology, Rajiv Gandhi Medical College, Kalwa, Maharashtra, India.

### NAME, ADDRESS, E-MAIL ID OF THE CORRESPONDING AUTHOR:

Dr. Vaibhav Bhika Bari,  
314, Nav Alankar Apt, Third Floor, Old Mumbai Pune Road, Kalwa, Thane-400605, Maharashtra, India.  
E-mail : vbbari@gmail.com

Date of Submission: Jan 27, 2015

Date of Peer Review: Feb 10, 2015

Date of Acceptance: Feb 21, 2015

Date of Publishing: Apr 01, 2015

FINANCIAL OR OTHER COMPETING INTERESTS: None.